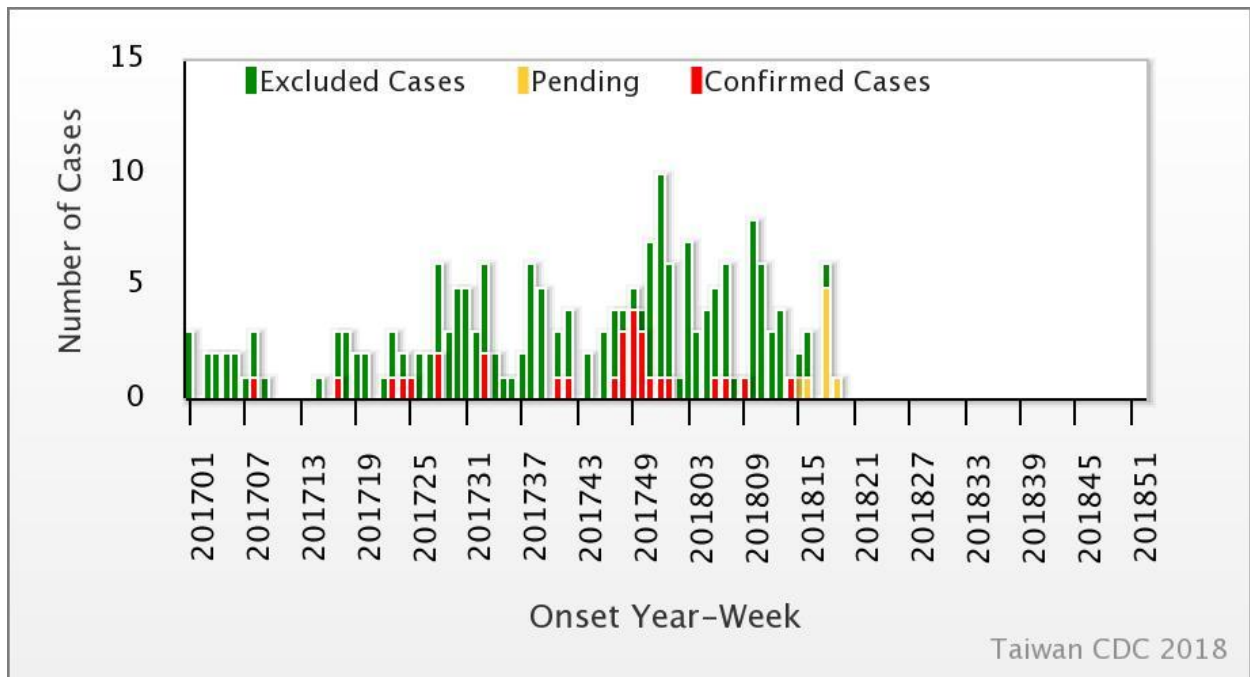




During Week 19 (May 6th to 12th) in 2018, no new severe case of enterovirus infection was confirmed (Figure 1). A total of five enterovirus infection cases with severe complications (EVSC) have been reported in 2018. These cases were caused by Coxsackie A4, Coxsackie B1, Coxsackie B2, and EV71. The majority of cases were below 1 year old (Table 1). Figure 2 shows the geographical distribution of these cases according to their residential areas.

Figure 1 Trend of EVSC, Taiwan, 2017~2018



For further information, please visit NIDSS website at <https://nidss.cdc.gov.tw/en/>



Table 1 Age and sex distribution of EVSC cases in 2018

Age(year)	Male	Female	Total
<1	2	1	3
1	0	0	0
2	0	0	0
3	1	0	1
4	0	1	1
5	0	0	0
6	0	0	0
7-9	0	0	0
≥ 10	0	0	0
Total	3	2	5



Figure 2 Geographical distribution of EVSC cases in 2018

