



# Weekly Report of Enterovirus Infection

During Week 14 (April 1<sup>st</sup> to 7<sup>th</sup>) in 2018, no new severe case of enterovirus infection was confirmed (Figure 1). There have been four enterovirus infection cases with severe complications (EVSC) in 2018. These cases were caused by Coxsackie A4, Coxsackie B1, and Coxsackie B2. The majority of cases were below 1 year old (Table 1). Figure 2 shows the geographical distribution of these cases according to their residential areas.

Figure 1 Trend of EVSC, Taiwan, 2017~2018

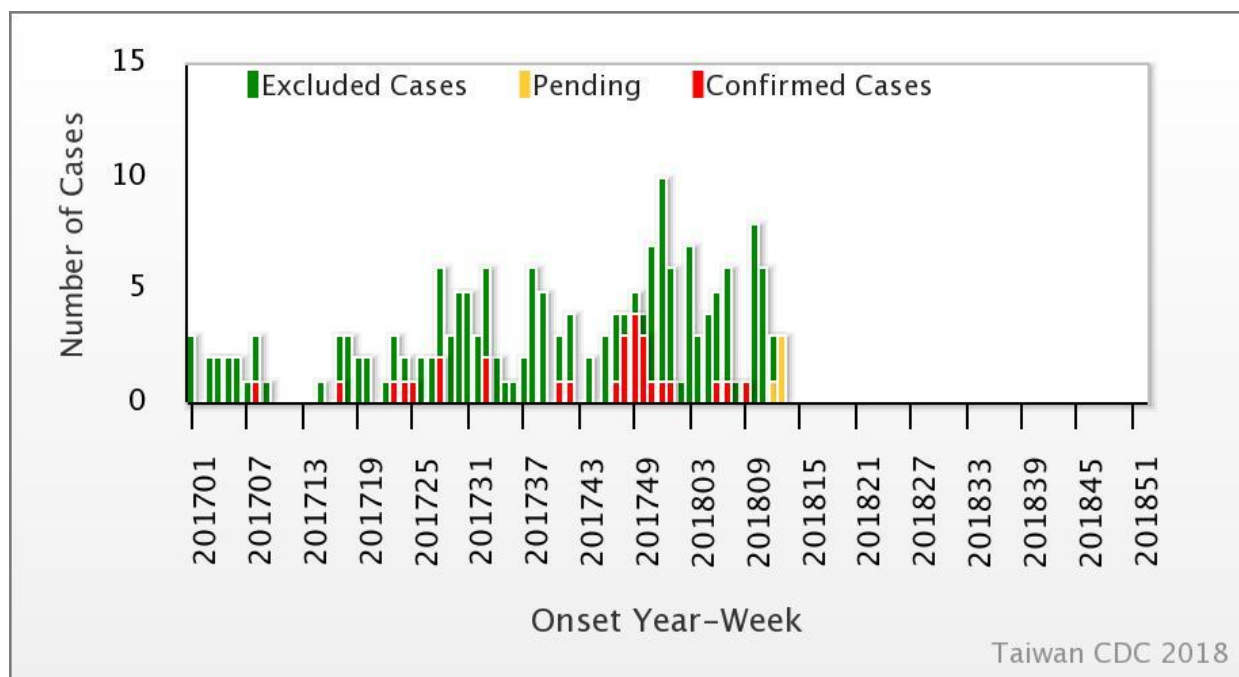


Table 1 Age and sex distribution of four EVSC cases in 2018

Age(year)	Male	Female	Total
<1	2	1	3
1	0	0	0
2	0	0	0
3	0	0	0
4	0	1	1
5	0	0	0
6	0	0	0
7-9	0	0	0
$\geq 10$	0	0	0
Total	2	2	4



Figure 2 Geographical distribution of four EVSC cases in 2018

