



Weekly Report of Enterovirus Infection

During Week 20 (May 13th to 19th) in 2018, two severe cases of enterovirus 71 (EV 71) and echovirus 11 (ECHO 11) infection were newly confirmed (Figure 1). A total of seven enterovirus infection cases with severe complications (EVSC) have been reported in 2018. These cases were caused by Coxsackie A4, Coxsackie B1, Coxsackie B2, EV 71, and ECHO 11. The majority of cases were below 1 year old (Table 1). Figure 2 shows the geographical distribution of these cases according to their residential areas.

Figure 1 Trend of EVSC, Taiwan, 2017~2018

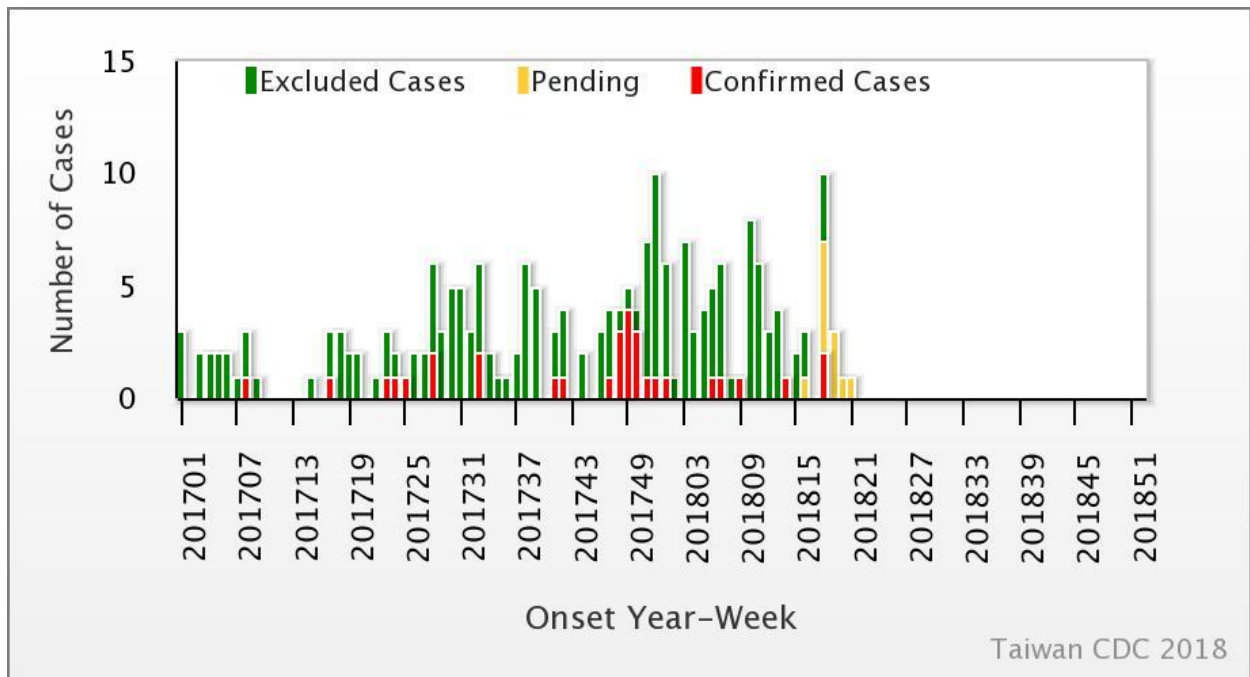


Table 1 Age and sex distribution of EVSC cases in 2018

Age(year)	Male	Female	Total
<1	3	1	4
1	0	0	0
2	0	0	0
3	1	1	2
4	0	1	1
5	0	0	0
6	0	0	0
7-9	0	0	0
≥ 10	0	0	0
Total	4	3	7



