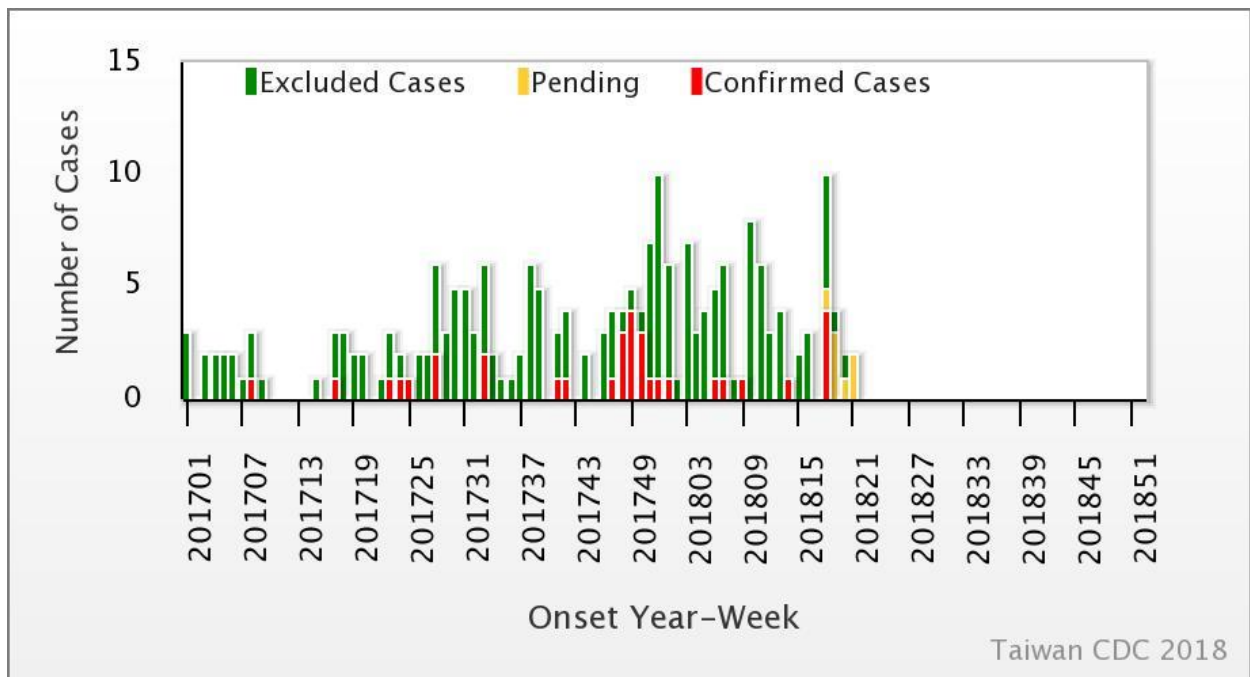




Weekly Report of Enterovirus Infection

During Week 21 (May 20th to 26th) in 2018, two severe cases of coxsackie A16 and coxsackie B3 infection were newly confirmed (Figure 1). A total of nine enterovirus infection cases with severe complications (EVSC) have been reported in 2018. These cases were caused by Coxsackie A4, Coxsackie A16, Coxsackie B1, Coxsackie B2, Coxsackie B3, EV 71, and ECHO 11. The majority of cases were below 3 years old (Table 1). Figure 2 shows the geographical distribution of these cases according to their residential areas.

Figure 1 Trend of EVSC, Taiwan, 2017~2018



For further information, please visit NIDSS website at <https://nidss.cdc.gov.tw/en/>



Table 1 Age and sex distribution of EVSC cases in 2018

Age(year)	Male	Female	Total
<1	3	1	4
1	1	0	1
2	0	1	1
3	1	1	2
4	0	1	1
5	0	0	0
6	0	0	0
7-9	0	0	0
≥ 10	0	0	0
Total	5	4	9



