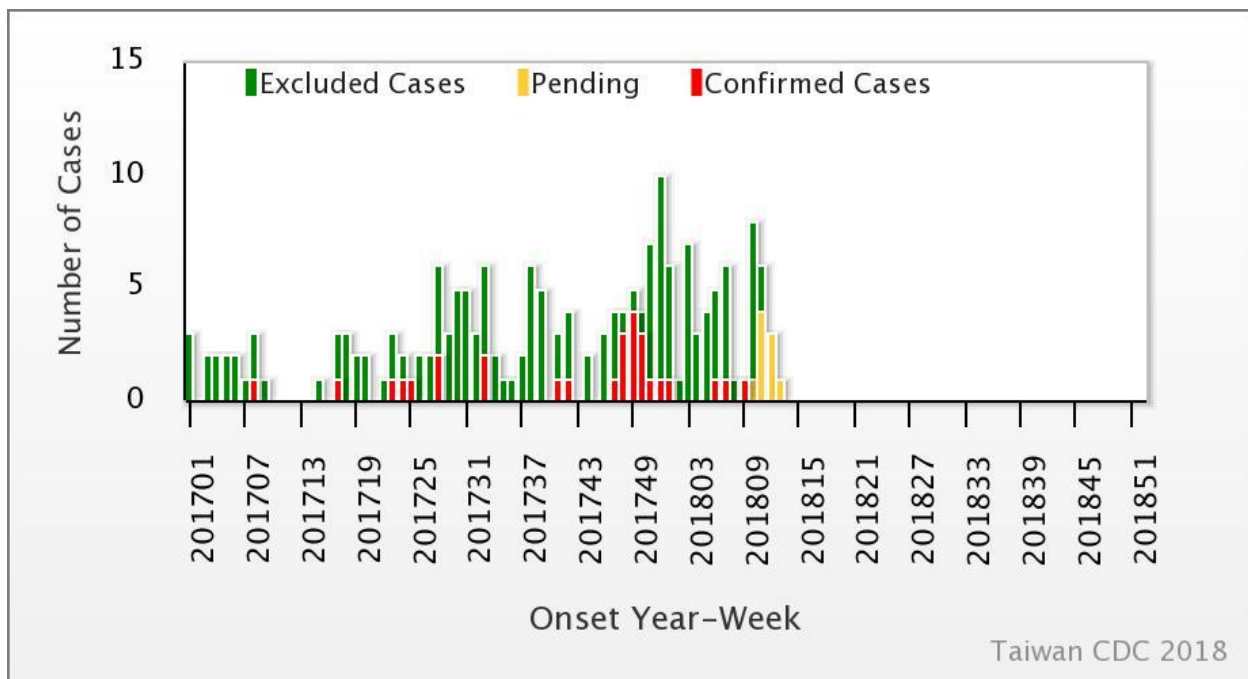




During Week 13 (March 25<sup>th</sup> to 31<sup>st</sup>) in 2018, no new severe case of enterovirus infection was confirmed (Figure 1). There have been four enterovirus infection cases with severe complications (EVSC) in 2018. These cases were caused by Coxsackie A4, Coxsackie B1, and Coxsackie B2. The majority of cases were below 1 year old (Table 1). Figure 2 shows the geographical distribution of these cases according to their residential areas.

Figure 1 Trend of EVSC, Taiwan, 2017~2018



For further information, please visit NIDSS website at <https://nidss.cdc.gov.tw/en/>



Table 1 Age and sex distribution of four EVSC cases in 2018

Age(year)	Male	Female	Total
<1	2	1	3
1	0	0	0
2	0	0	0
3	0	0	0
4	0	1	1
5	0	0	0
6	0	0	0
7-9	0	0	0
$\geq 10$	0	0	0
Total	2	2	4



