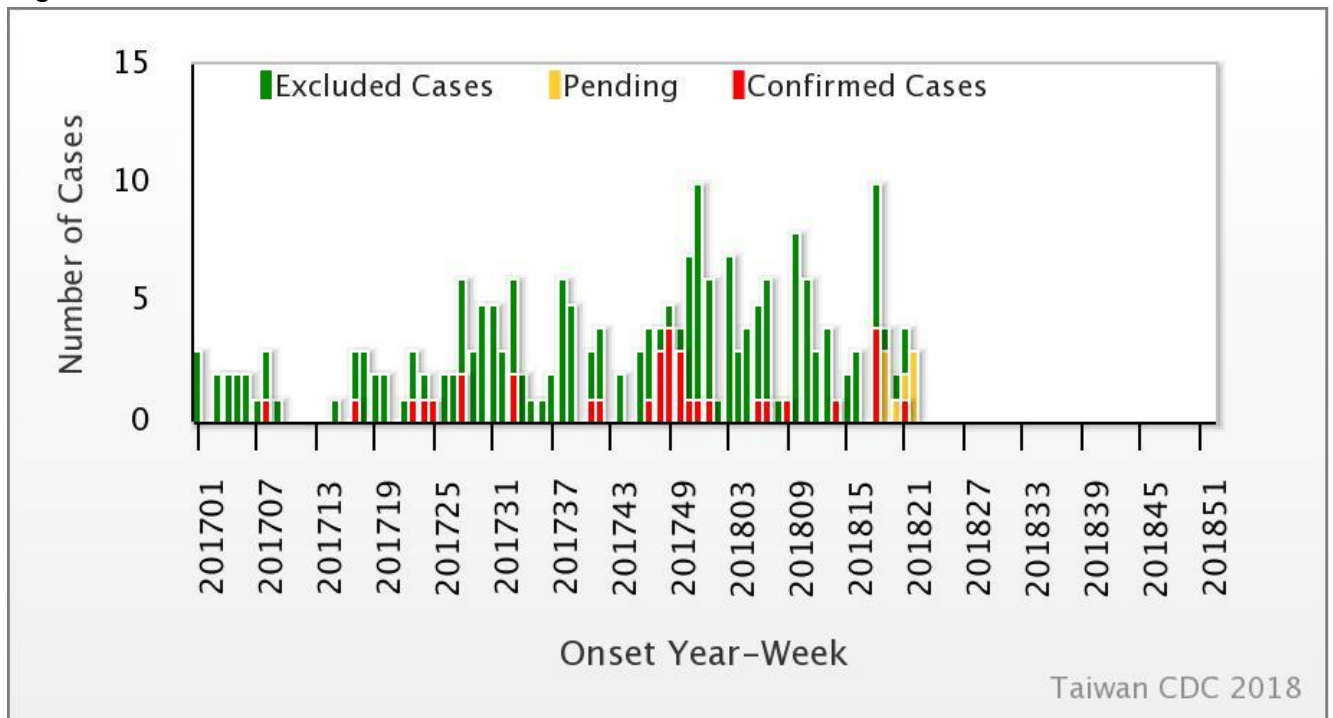




Weekly Report of Enterovirus Infection

During Week 22 (May 27th to June 2nd) in 2018, one severe case of echovirus 11 (ECHO 11) infection was newly confirmed (Figure 1). There have been 10 cases of enterovirus infection cases with severe complications (EVSC) in 2018. These cases were caused by Coxsackie A4, Coxsackie A16, Coxsackie B1, Coxsackie B2, Coxsackie B3, EV 71, and ECHO 11. Fifty percent of cases were below 1 year old (Table 1). Figure 2 shows the geographical distribution of these cases according to their residential areas.

Figure 1 Trend of EVSC, Taiwan, 2017~2018



For further information, please visit NIDSS website at <https://nidss.cdc.gov.tw/en/>



Table 1 Age and sex distribution of EVSC cases in 2018

年齡 (歲)	男性	女性	總計
<1	4	1	5
1	1	0	1
2	0	1	1
3	1	1	2
4	0	1	1
5	0	0	0
6	0	0	0
7-9	0	0	0
≥10	0	0	0
總計	6	4	10



Figure 2 Geographical distribution of EVSC cases in 2018

