



Weekly Report of Enterovirus Infection

During Week 25 (June 17th to 23rd) in 2018, one severe case of echovirus 11 (ECHO 11) infection were newly confirmed (Figure 1). There have been 16 cases of enterovirus infection with severe complications (EVSC) in 2018, including three deaths due to ECHO 11 infection. These cases were caused by Coxsackie A4, A9, A16, Coxsackie B1, B2, B3, EV71, and ECHO 11. Fifty percent of cases were below 1 year old (Table 1). Figure 2 shows the geographical distribution of these cases according to their residential areas.

For further information, please visit the Taiwan National Infectious Disease Statistics System (NIDSS) website at <https://nidss.cdc.gov.tw/en/>

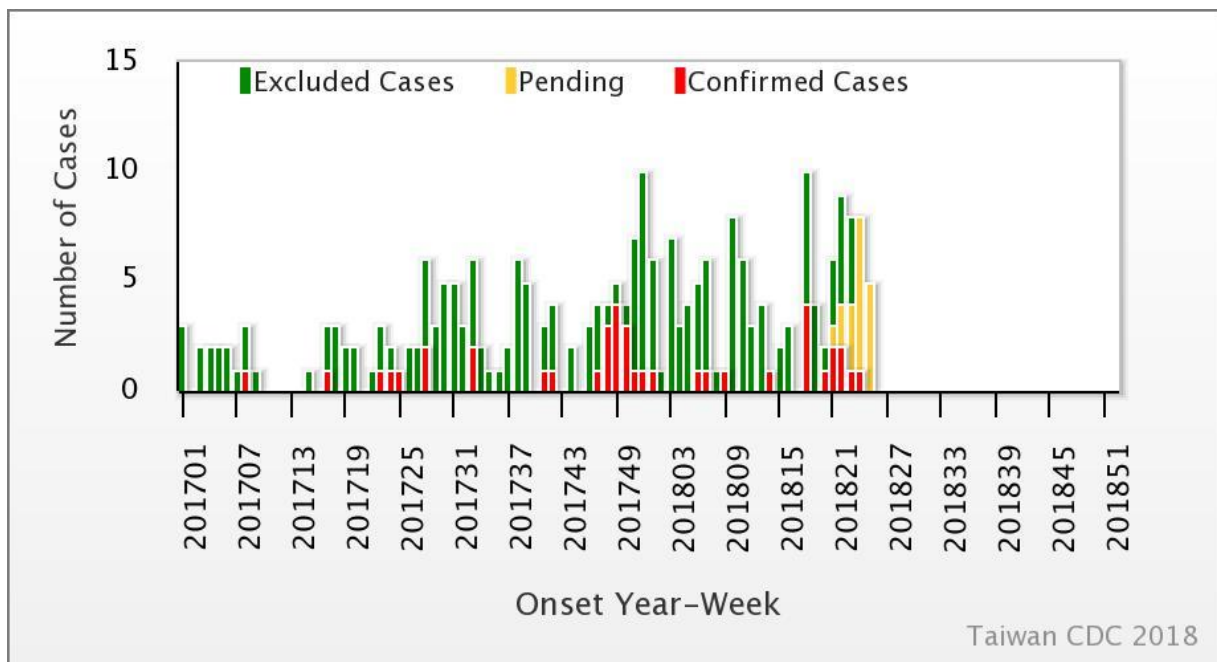


Figure 1. Trend of EVSC, 2017-2018



Table 1. Age and sex distribution of EVSC cases in 2018

Age(year)	Male	Female	Total
<1	6	2	8
1	1	0	1
2	0	1	1
3	2	1	3
4	0	2	2
5	1	0	1
6	0	0	0
7-9	0	0	0
≥ 10	0	0	0
Total	10	6	16

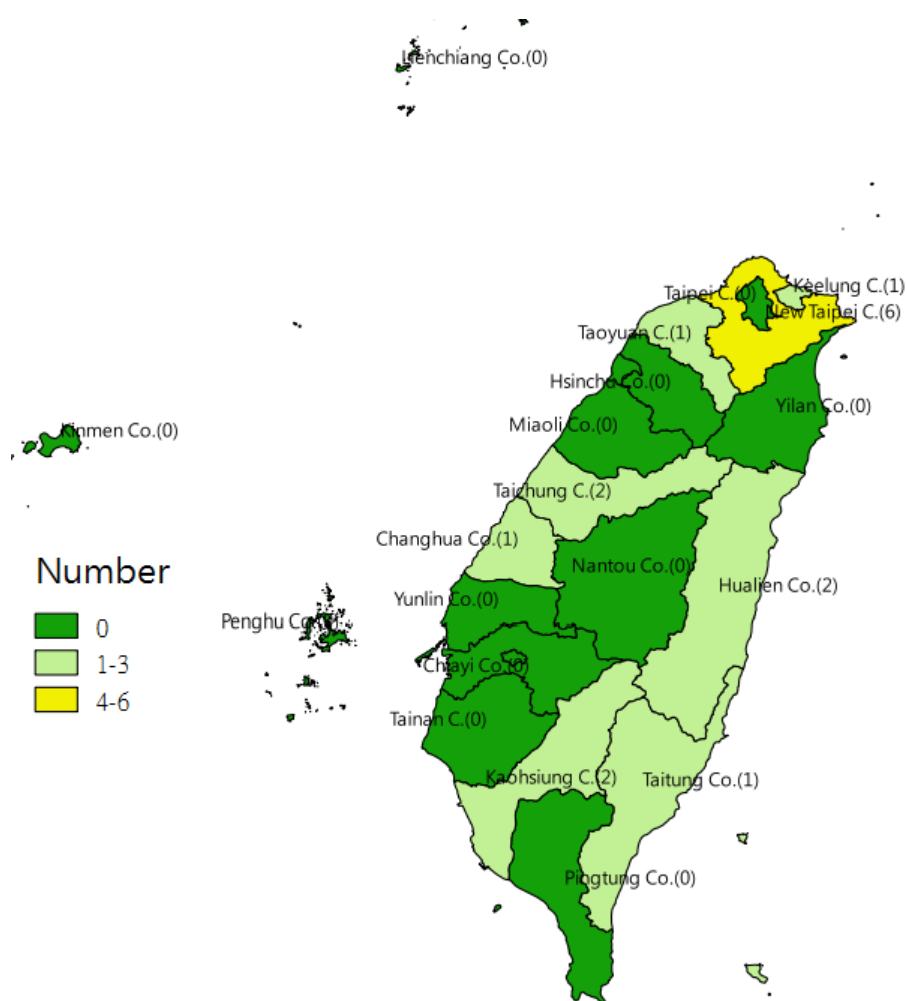


Figure 2. Geographical distribution of EVSC cases in 2018

