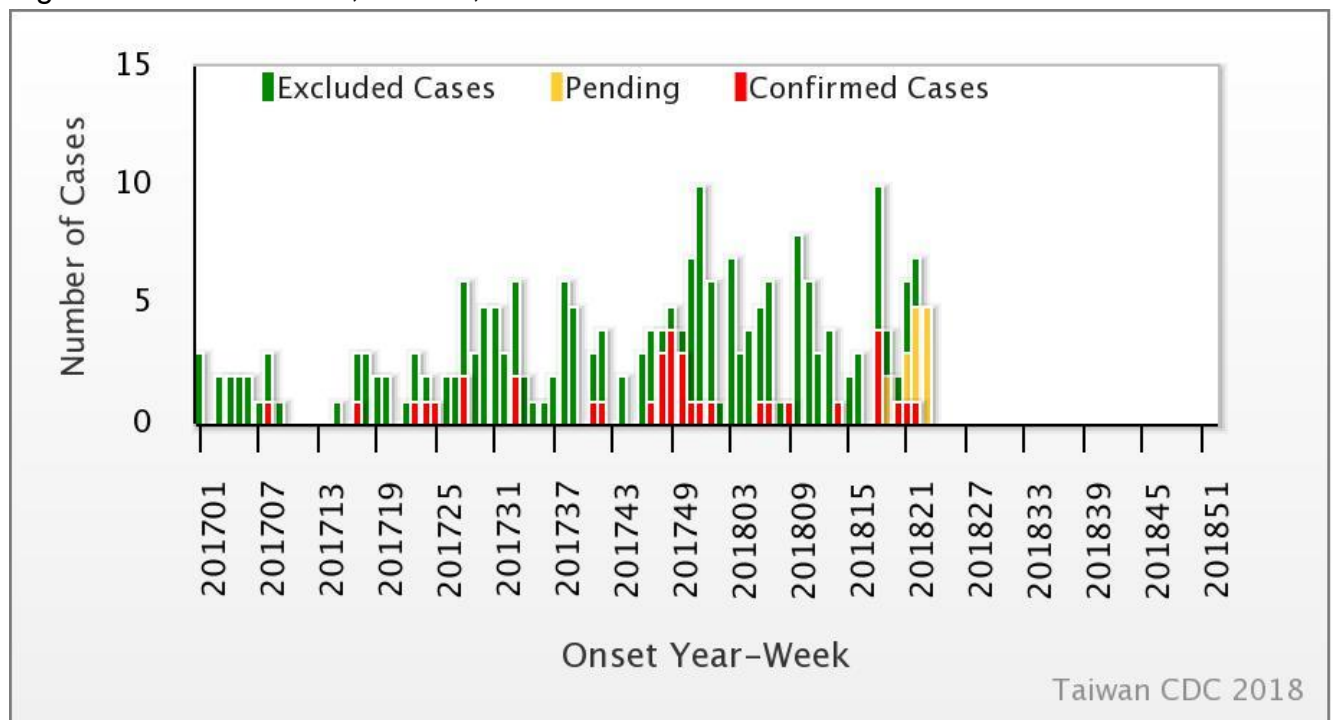




Weekly Report of Enterovirus Infection

During Week 23 (June 3rd to 9th) in 2018, two severe cases of echovirus 11 (ECHO 11) infection were newly confirmed (Figure 1). There have been 12 cases of enterovirus infection with severe complications (EVSC) in 2018, including two deaths due to ECHO 11 infection. These cases were caused by Coxsackie A4, Coxsackie A16, Coxsackie B1, Coxsackie B2, Coxsackie B3, EV 71, and ECHO 11. Fifty-eight percent of cases were below 1 year old (Table 1). Figure 2 shows the geographical distribution of these cases according to their residential areas.

Figure 1 Trend of EVSC, Taiwan, 2017~2018



For further information, please visit NIDSS website at <https://nidss.cdc.gov.tw/en/>



Table 1 Age and sex distribution of EVSC cases in 2018

Age(year)	Male	Female	Total
<1	5	2	7
1	1	0	1
2	0	1	1
3	1	1	2
4	0	1	1
5	0	0	0
6	0	0	0
7-9	0	0	0
≥ 10	0	0	0
Total	7	5	12



Figure 2 Geographical distribution of EVSC cases in 2018

