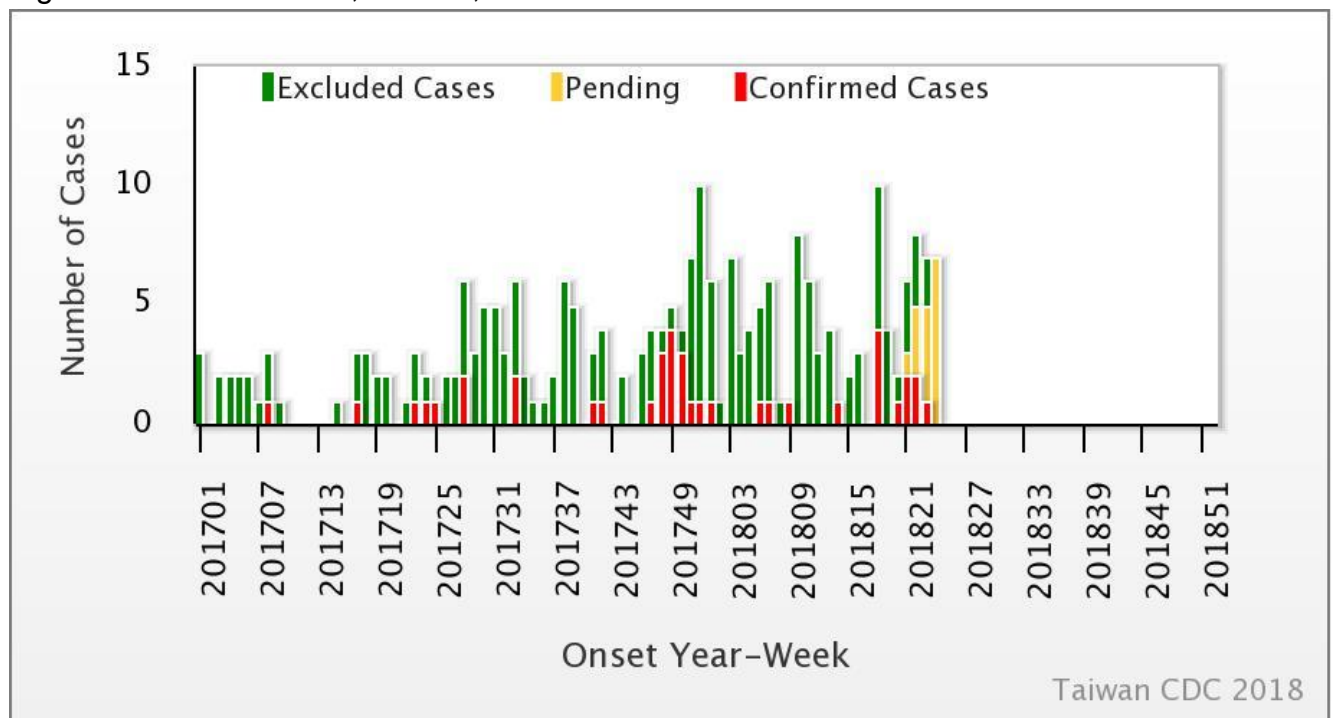




Weekly Report of Enterovirus Infection

During Week 24 (June 10th to 16th) in 2018, three severe cases of Coxsackie A4, Coxsackie A9, and echovirus 11 (ECHO 11) infection were newly confirmed (Figure 1). There have been 15 cases of enterovirus infection with severe complications (EVSC) in 2018, including two deaths due to ECHO 11 infection. These cases were caused by Coxsackie A4, Coxsackie A9, Coxsackie A16, Coxsackie B1, Coxsackie B2, Coxsackie B3, EV71, and ECHO 11. Forty-seven percent of cases were below 1 year old (Table 1). Figure 2 shows the geographical distribution of these cases according to their residential areas.

Figure 1 Trend of EVSC, Taiwan, 2017~2018



For further information, please visit NIDSS website at <https://nidss.cdc.gov.tw/en/>



Table 1 Age and sex distribution of EVSC cases in 2018

Age(year)	Male	Female	Total
<1	5	2	7
1	1	0	1
2	0	1	1
3	2	1	3
4	0	2	2
5	1	0	1
6	0	0	0
7-9	0	0	0
≥ 10	0	0	0
Total	9	6	15



Figure 2 Geographical distribution of EVSC cases in 2018

